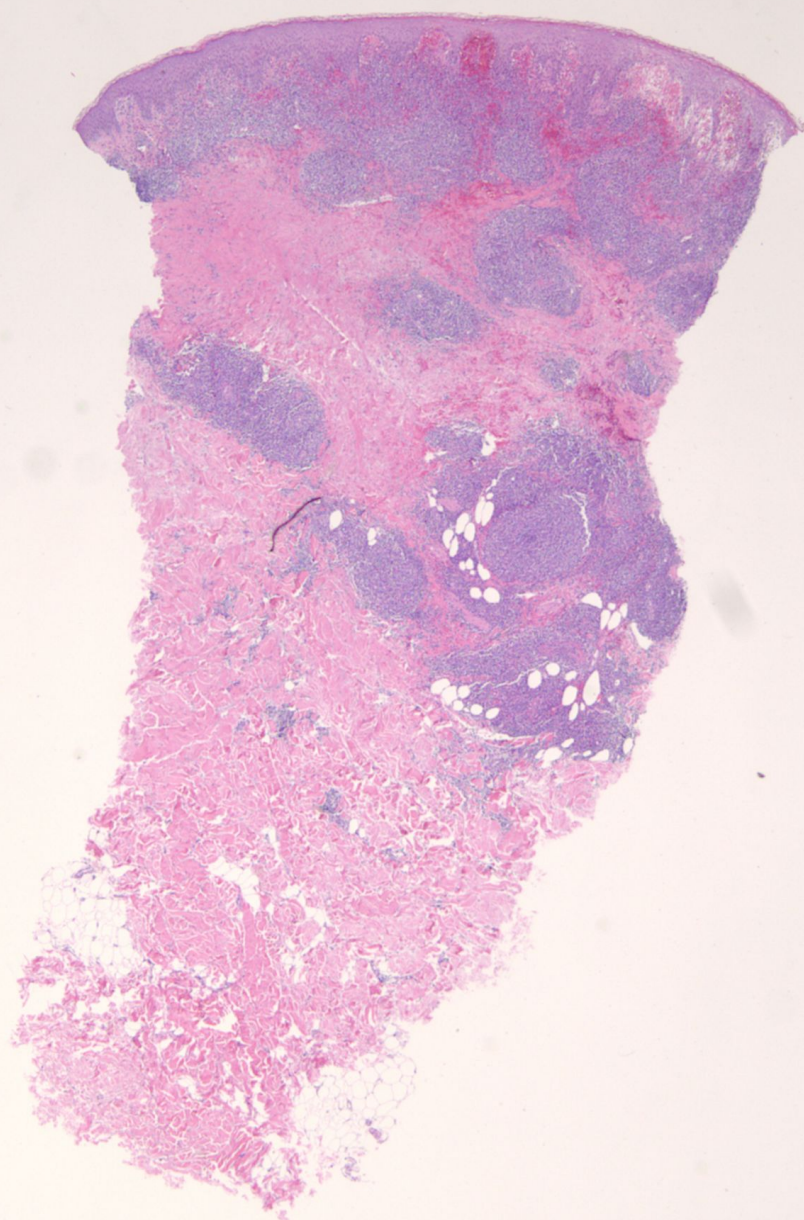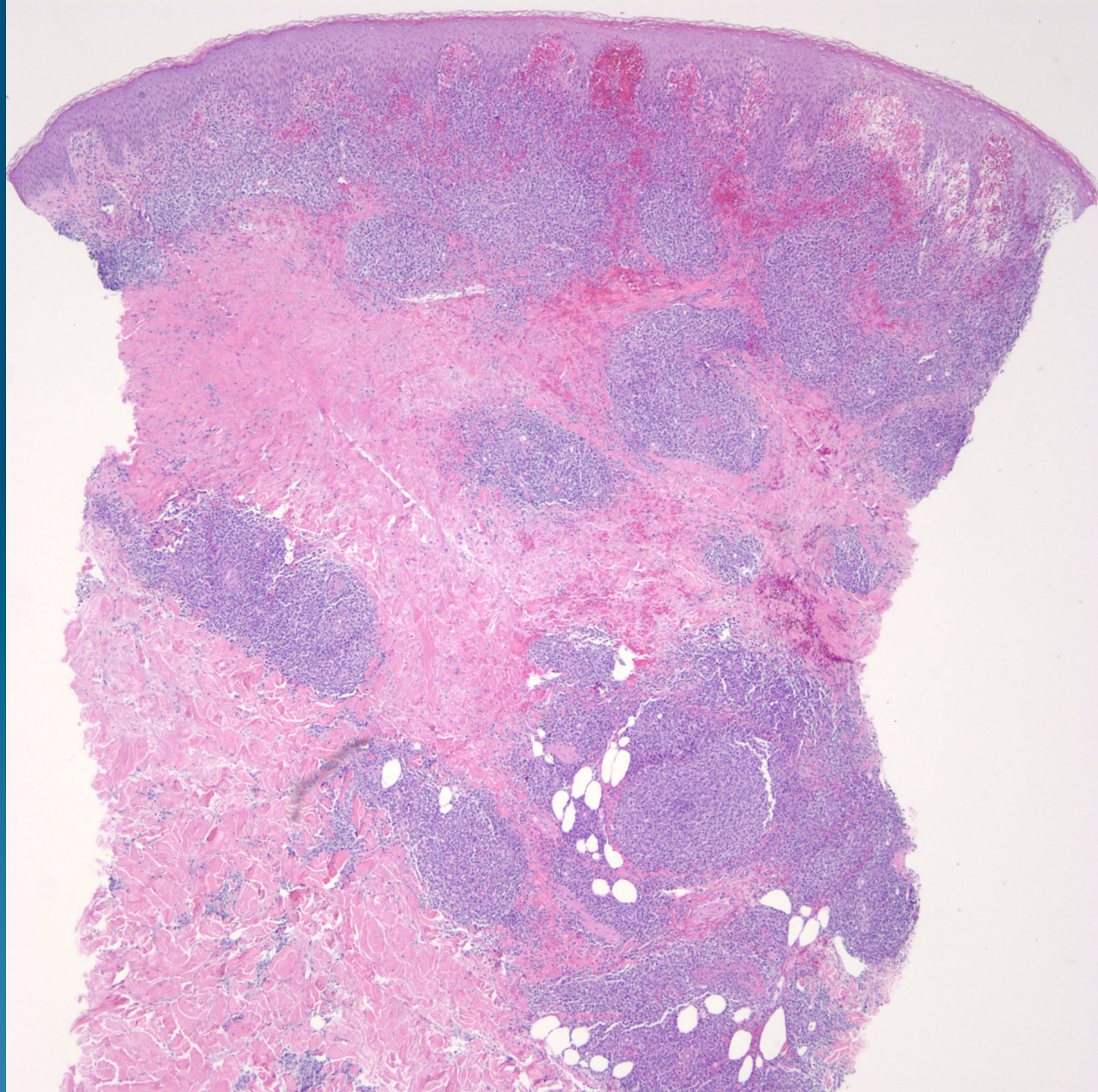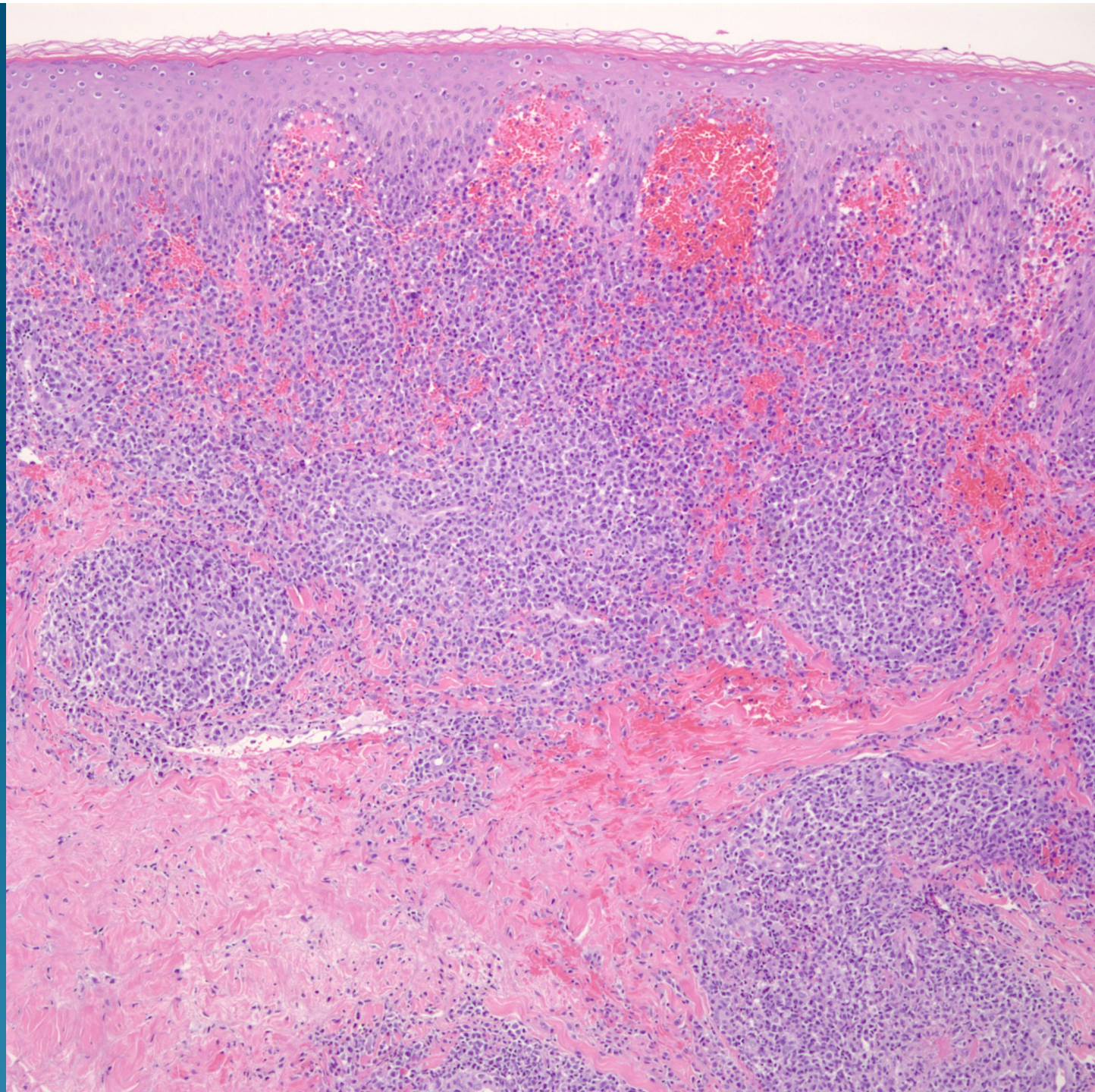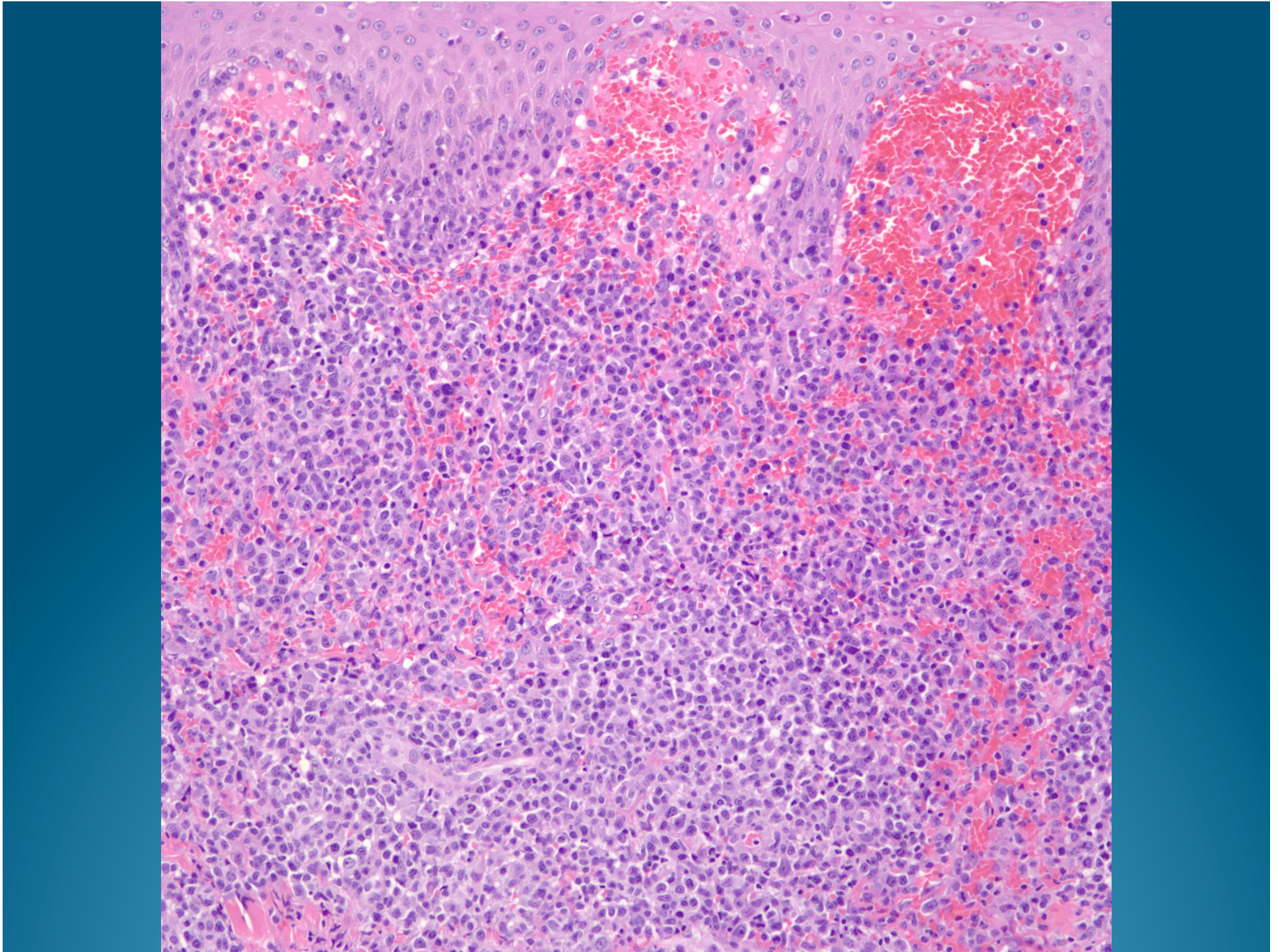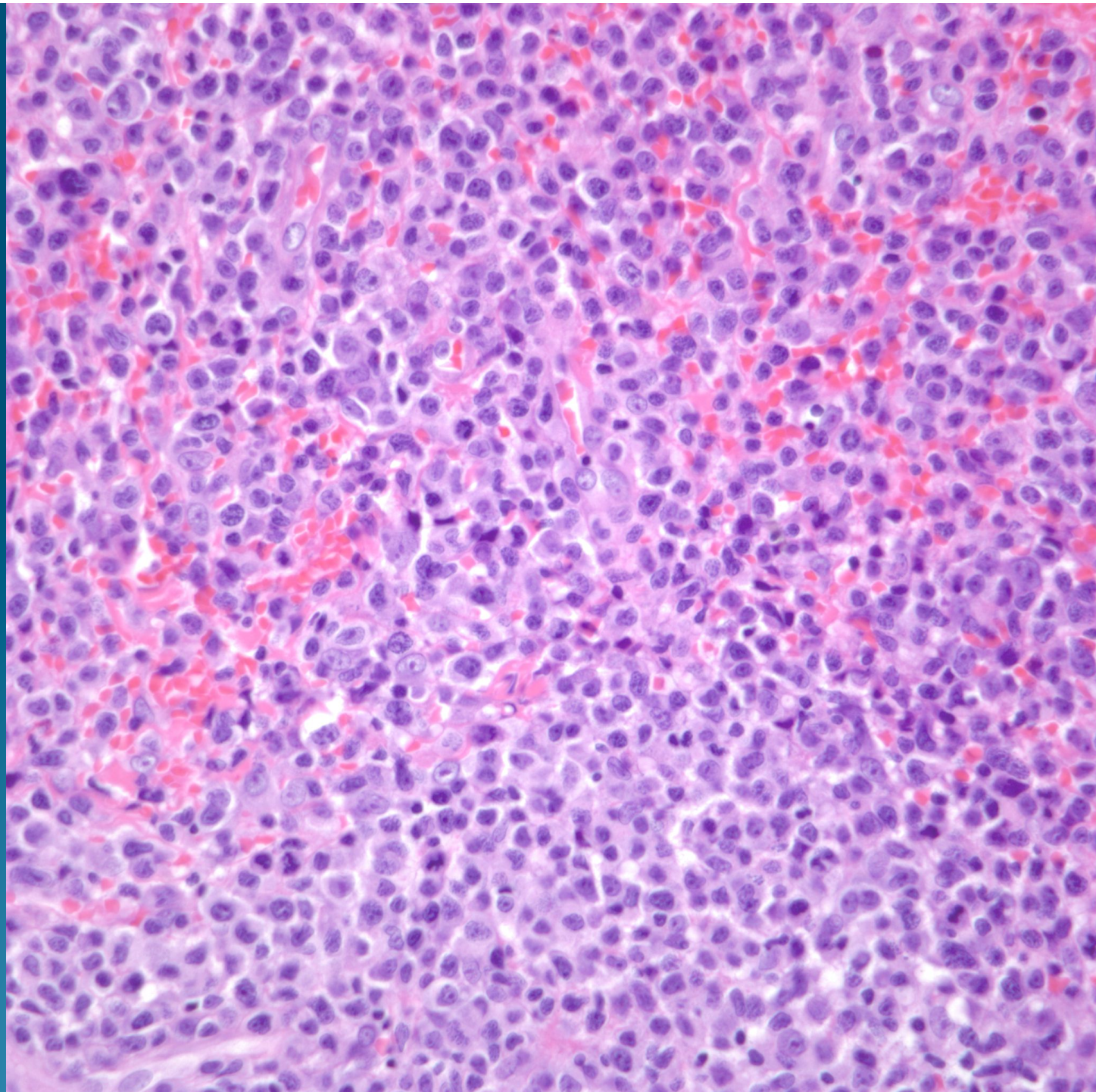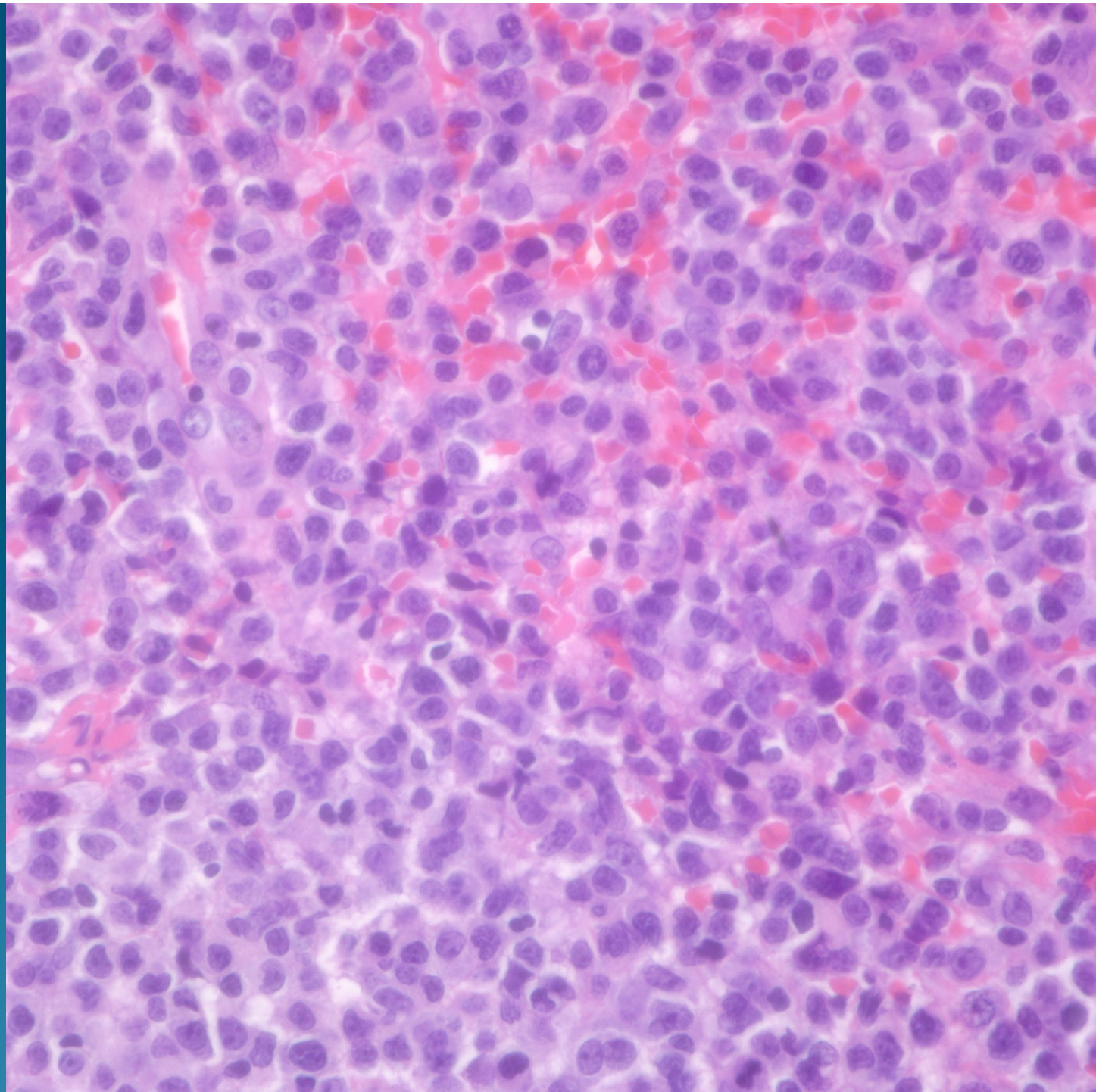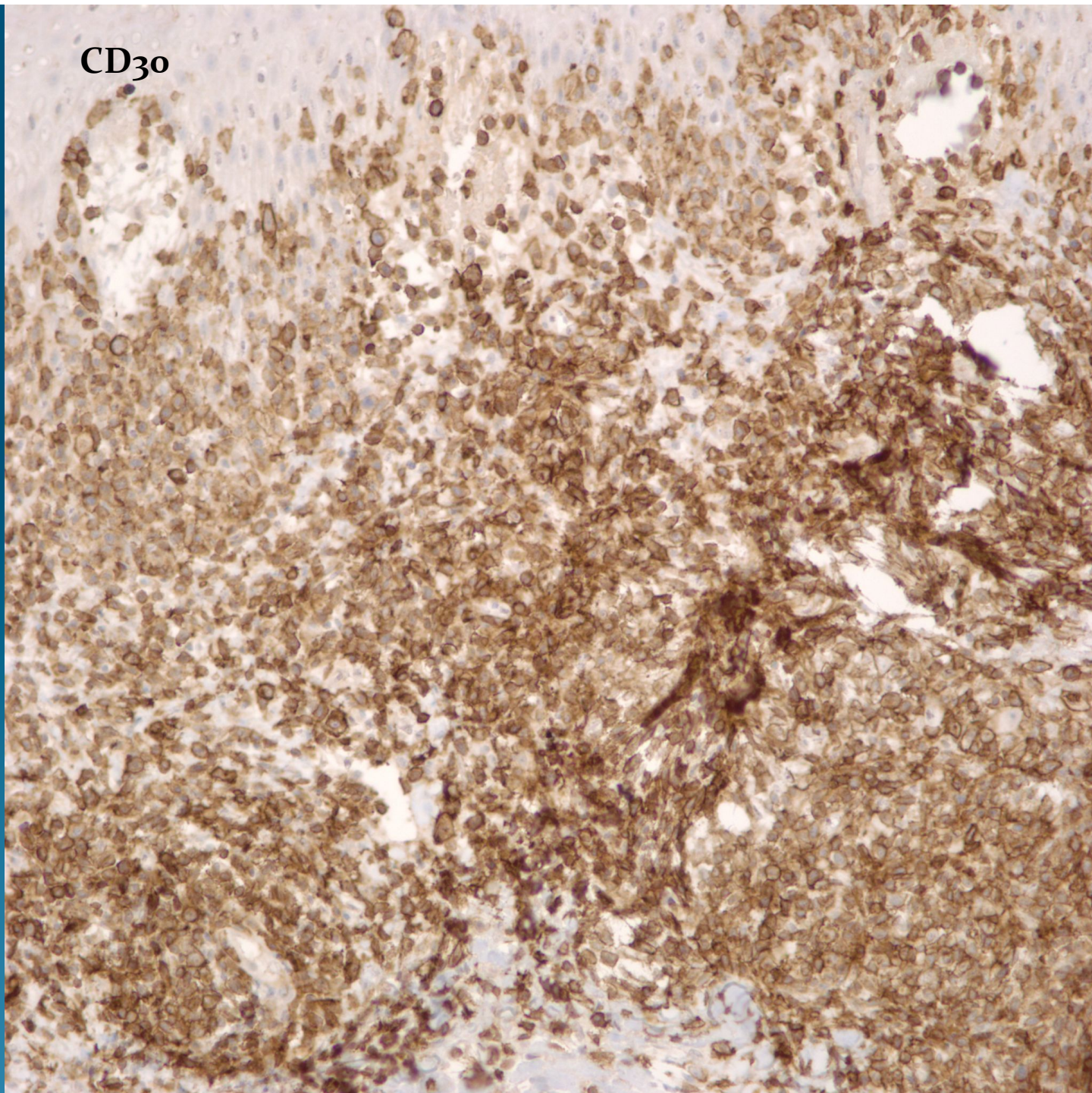


What is the best diagnosis?

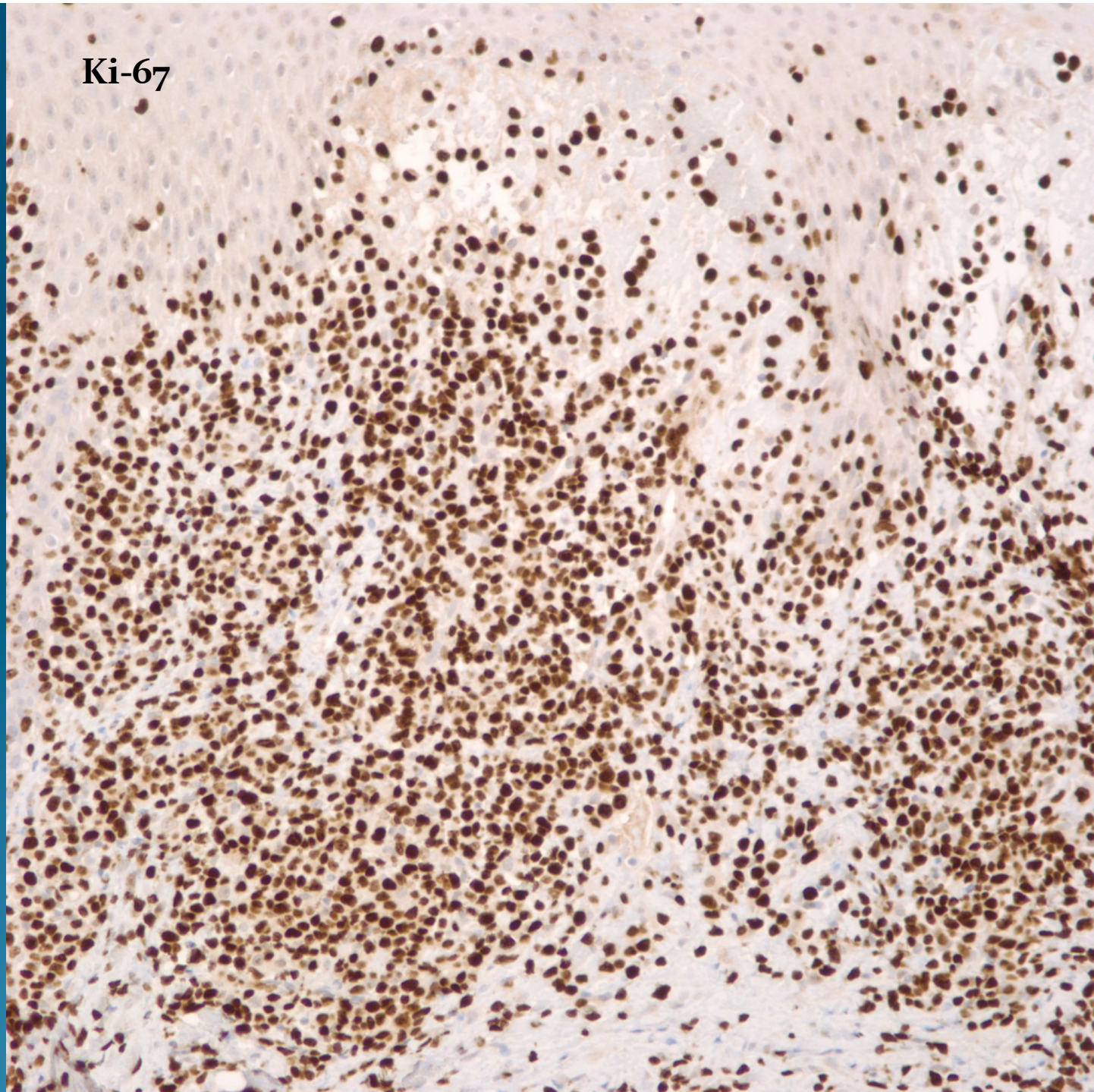
- A. Intravascular lymphoma
- B. CD30 lymphoproliferative disorder
- C. Mastocytoma
- D. Hodgkin's disease
- E. Malignant melanoma

CD30+ Lymphoproliferative Disorder-Consistent with Lymphomatoid Papulosis

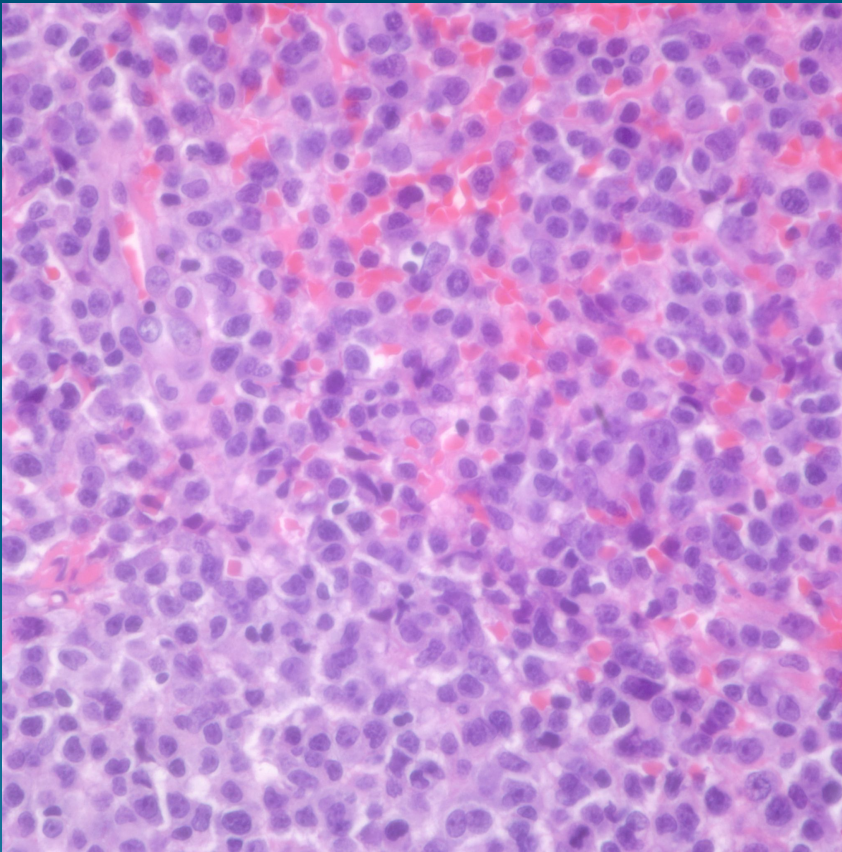
CD30



Ki-67



Pearls



- Diffuse and sometimes wedge shaped infiltrate of pleomorphic lymphoid cells
- May be admixed with mixed inflammatory cells simulating an inflammatory dermatosis
- Confirm with CD30
- Rule out anaplastic CD30+ lymphoma-may be clinical pathologic correlation